

## Research Paper

# The Pharmacology Study of a New Recombinant Human VEGF Receptor-Fc Fusion Protein on Experimental Choroidal Neovascularization

Ming Zhang,<sup>1</sup> Dechao Yu,<sup>2</sup> Chun Yang,<sup>2</sup> Qingjie Xia,<sup>1</sup> Wang Li,<sup>3</sup> Bin Liu,<sup>3</sup> and Hong Li<sup>2,4</sup>

Received March 4, 2008; accepted August 22, 2008; published online October 15, 2008

**Purpose.** KH902, a recombinant fusion protein, is designed for treatment of neovascular age-related macular degeneration. The study is to investigate the prevention efficacy of KH902 on experimental choroidal neovascularization (CNV) in a monkey model.

**Materials and Methods.** Binding assay and endothelial cell proliferation assay were used to evaluate activity and bioactivity of KH902 *in vitro* while an initial comparison of bioactivity was made between KH902 and Ranizumab (Lucentis). Ocular and systemic levels of KH902 were analyzed by enzyme-linked immunosorbent assay (ELISA) method after single intravitreal administration to evaluate its availability to ocular fundus. *In vivo* pharmacological study, CNV was induced by laser in monkeys and KH902 prevention efficacy on CNV was evaluated by incidence of CNV and several ophthalmic examinations.

**Results.** KH902 is a unique fusion protein with high affinity to VEGF and good availability to target tissue, beneficial to good bioactivity *in vivo*. *In vivo* pharmacological study, the incidence of CNV formation was largely reduced in KH902 treatment groups. Furthermore, the leakage of CNV in control group which crossed over to KH902 treatment 40 days after laser was much less than that before KH902 treatment.

**Conclusion.** KH902 was effective to prevent the formation of experimental CNV and also to treat pre-existed CNV without evidence of toxicity. This study suggests that KH902 has promise as a local anti-angiogenic treatment of CNV-related diseases.

**KEY WORDS:** age-related macular degeneration; antiangiogenesis; choroidal neovascularization; intravitreal injection; vascular endothelial growth factor receptor.

## INTRODUCTION

The choroidal neovascularization (CNV) accounts for the severely progressive visual loss in wet age-related macular degeneration (AMD) (1–3). These new vessels can leak and bleed, leading to exudative retinal detachment and hemorrhage. The vascular endothelial growth factor (VEGF) is reported to be a major factor of angiogenesis and vascular permeability implicated in the development of the CNV. And high level of VEGF is detected in the AMD of different forms and stages (4).

The therapies that aim at the VEGF as the target for the management of CNV associated with AMD recently demonstrates encouraging signs of biological activity. One

strategy is to intravitreally inject aptamers or anti-VEGF antibodies, such as Macugen or Ranibizumab (Lucentis, the Fab of Bevacizumab). Soluble VEGF receptors also provide a very specific and good way to antagonize VEGF. Several studies have demonstrated that the extracellular domains of VEGF receptors has anti-angiogenic activity (5).

KH902 is a recombinant fusion protein which contains several ligand binding domains of human VEGF receptor 1 (Flt-1) and 2 (KDR) and the Fc portion of human IgG1. Based on studies *in vitro*, KH902 has high affinity to VEGF and good potency of inhibition on VEGF-induced endothelial cell proliferation. This study is to investigate the prevention effect of KH902 at two intravitreal intervals on the experimental CNV as well as the pilot treatment on pre-existed experimental CNV.

<sup>1</sup>Department of Ophthalmology, West China Hospital, Sichuan University, Chengdu, Sichuan 610041, China.

<sup>2</sup>Chengdu Kanghong Biotechnology Co. Inc., 36 ShuXi Road, JinNiu District, Chengdu, Sichuan Province 610036, China.

<sup>3</sup>State Chengdu Traditional Chinese Medicine Safety Evaluation Center, Chengdu, Sichuan 610041, China.

<sup>4</sup>To whom correspondence should be addressed. (e-mail: cissi\_79@yahoo.com.cn)

**ABBREVIATION:** AMD, age-related macular degeneration; CNV, choroidal neovascularization; HUVEC, human umbilical vein endothelial cell; OCT, optical coherent tomography; VEGF, vascular endothelial growth factor.

## MATERIALS AND METHODS

### KH902

KH902 is an engineered protein which comprises the extra-cellular domain 2 of VEGFR1 and extra-cellular domains 3, and 4 of VEGFR2 fused to the Fc portion of human IgG1. The molecular weight is about 143 kD. The PI was detected using IEF method.

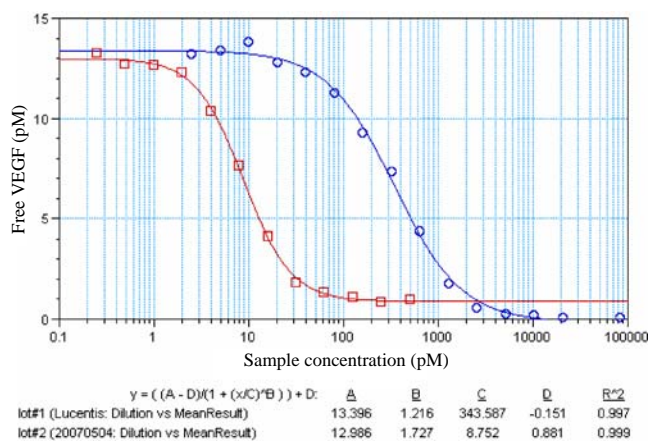
**Table I.** Experimental Design of KH902 Pharmacology in Rhesus Monkeys

Group	Day 0 <sup>a</sup>	Day 7	Day 14	Day 20	Day 40
KH902 prevention 1	KH902 640 µg	KH902	KH902	KH902	
KH902 prevention 2	KH902 640 µg	–	KH902	–	
Left eye of control	Buffer 40 µL	–	Buffer	–	KH902 640 µg
Right eye of control	Buffer 40 µL	–	Buffer	–	Buffer 40 µL

<sup>a</sup>Day 0: the day receiving laser burn and also the first dose

### VEGF Binding Assay of KH902 and HUVEC Proliferation Assay

Two assays on VEGF were taken to evaluate KH902 efficacy *in vitro* (6). At the same time, the comparison between KH902 and Ranibizumab (Lucentis) was made. Briefly, binding affinity with VEGF was measured by using the human VEGF ELISA kit (DY293B; R&D, Minneapolis, MN, USA) for detecting free human VEGF in mixtures of KH902 or Lucentis and 10 pM human VEGF. The procedure of the assay is described in the protocol provided by the kit. After the spectrophotometric method used had been validated, free human VEGF was calculated using 4 parameters curve with the absorbance value measured at 450/570 nm. And the affinity of KH902 and Lucentis was compared in term of IC<sub>50</sub>. To further evaluate the bioactivity of KH902, the proliferation of human umbilical vein endothelial cells (HUVECs) was taken as a good index. HUVECs were cultured in conditioned medium containing 20 ng/mL VEGF and serial concentrations of KH902 (586.9, 352.1, 195.6, 105.6, 65.2, 35.2, 21.7, 7.2, 2.42, and 0 pM) or Lucentis (30385, 10128, 3376, 1125, 375.1, 125, 41.68, 13.89, 4.63, 1.54 and 0 pM). Four days later, 15 µl CCK-8 (Dojindo Molecular Technologies, Kumamoto, Japan) was added into each well and the absorbance was measured at 570/630 nm after 2 h.

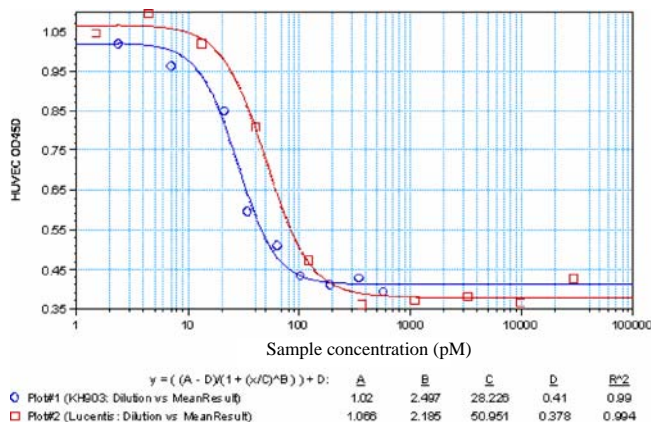


**Fig. 1.** KH902 high affinity to VEGF by using VEGF binding assay that measured free VEGF (*ordinate*) after incubation of about 10 pM of human VEGF<sub>165</sub> with varying concentrations of sample (*abscissa*). The red line indicated KH902 binding capacity with IC<sub>50</sub> was 8.8 pM. The blue line with circles illustrated Lucentis IC<sub>50</sub> was about 343 pM.

### KH902 Pharmacokinetic Analysis

**Animals.** Twelve rhesus monkeys in this experiment were used in compliance with guidelines developed by the Animal Care Committee of the government (Chengdu, China). Monkeys weighed between 2 and 5 kg, and ages ranged from 3 to 6 years. For the experimental procedures, animals were anesthetized with 2.5% soluble pentobarbitone (1 mL/kg). Supplemental anesthesia was given with 2.5% soluble pentobarbitone (0.8 mL/kg). Topical ocular anesthesia was obtained with proparacaine.

Six monkeys were given a single intravitreal injection of KH902 0.5 mg into each eye to analyze the distribution and penetration in eye and serum of KH902. Two monkeys were sacrificed and four eyes were enucleated respectively at 2, 7, 15 days after dose. KH902 concentrations were determined in the vitreous, aqueous humor, iris, neural retina (NR) and choroid tissues. Dissected choroid tissues were composed of the retinal pigment epithelium/Bruch's membrane/choroid (RPE/Bruch's/choroid), under a magnifying device. Dissections were completed within 30 min of euthanasia. After the solid tissues were homogenized, they were stored below -40°C for distribution analysis. In addition, sera were collected from the two monkeys sacrificed at 15 days at each time point (1, 4, 8, 18, 26, 42, 48, 72, 96, 120, 144, 168, 216, 264, 312, 360 h postdose). KH902 concentrations were analyzed with enzyme-linked immunosorbent assay (ELISA) method. For ELISA used in this pharmacokinetics, accuracy ranged from 88% to 113% with intra- and interassay coefficients of variation ranging 3~15% and 8~16%, respectively. The LLOQ is 0.437 ng/mL, the concentration range is 0.437~28 ng/mL.



**Fig. 2.** Blockage on the VEGF-induced HUVEC proliferation. The blue line with circles indicated KH902 inhibition on endothelial cell proliferation with EC<sub>50</sub> of 28 pM. The red line illustrated Lucentis EC<sub>50</sub> was 50 pM.

**Table II.** KH902 Ocular Distribution after Intravitreal Injection ( $\bar{X} \pm SD$ ,  $\mu\text{g/g}$  tissue)

Tissues	2 days after dose	7 days after dose	15 days after dose
Aqueous humor <sup>a</sup>	52.64±23.63	31.48±2.35	6.41±0.71
Vitreous humor	278.45±95.08	75.68±1.91	25.29±10.75
Lens	39.50±14.61	21.58±9.90	7.74±5.78
Retina	2.54±0.59	6.72±2.94	3.22±2.15
Chorioid	7.48±4.41	1.99±0.43	1.43±0.63
Iris	21.02±10.32	6.46±1.34	1.61±0.54

<sup>a</sup> KH902 concentrations, reported as micrograms per gram of tissue, equivalent to micrograms per milliliter.

KH902 serum pharmacokinetics was determined with a two-compartment model. All analyses were performed using DAS, ver. 1.0 (China).

### Inhibition Assay of Laser-Induced CNV by KH902

**Induction of Experimental CNV.** CNV was induced by a laser (Vissulas 532 s Laser Photocoagulator, Carl Zeiss Meditec AG, Jena, Germany). Laser photocoagulations were conducted to the perimacular region of both eyes. Lesions were placed in the macula with six to nine spots. Laser lesions were placed in a circular fashion around the macula about one disk diameter from the foveal center. The approximate laser parameters were as follows: spot size, 50  $\mu\text{m}$ ; laser power, 240 mW; and exposure time, 0.05 s. Color photographs were taken on the day of laser. The ultimate laser power used was determined by the appearance of a small blister and the sound of a pop indicating puncture of Bruch's membrane. If no blister or pop was noted, a second laser spot was placed over the initial spot.

**Intravitreal Injection of KH902 and Control.** The experimental design was summarized in Table I. In the same day after laser burn (d0), six monkeys were randomly divided into three groups. The treatment groups received intravitreal injection of KH902 at 640  $\mu\text{g}/40 \mu\text{L}$  biweekly or weekly and control group was administrated phosphate buffer in the same way. Before intravitreal injection, both eyes of each monkey should be administrated at least eight times tobramycin drops in the fornices. After the animal was anesthetized, the eye was topically anesthetized using a drop of proparacaine in the conjunctival sac and diluted the pupil using 0.5% tropicamide eye drops (Mydrin P, Santen Pharmaceutical, Osaka, Japan). A 5% povidone iodine solution was placed in the conjunctival sac. A self-retaining eyelid speculum was placed in the eye. We used calipers to measure and mark a location 2~3 mm behind the limbus. We used forceps to stabilize the eye and performed the intravitreal injection with a 30-gauge needle. The needle was visualized in the pupil and the drug or placebo was injected into the midvitreous. We withdrew the needle and instilled erythromid ointment into the fornices. The control group and one KH902 treatment group at 2-week interval received two intravitreal injections. And another KH902 treatment group at 1-week interval received four intravitreal injections. In addition, 40 days after laser when the neovascularization was evidenced by ocular examination, the left eye of one control monkey was administered KH902 at 640  $\mu\text{g}/40 \mu\text{L}$  and the right eye was still administered phosphate buffer.

**General Ophthalmologic Examination.** General ophthalmologic examinations were frequently performed to observe

fundus using indirect ophthalmoscopy. The animals were slightly sedated with ketamine hydrochloride before this procedure, and a few drops of 0.5% tropicamide and 0.4% oxybuprocaine hydrochloride (Benoxil.RTM. 0.4% solution, Santen Pharmaceutical) were instilled into each eye to facilitate the examination.

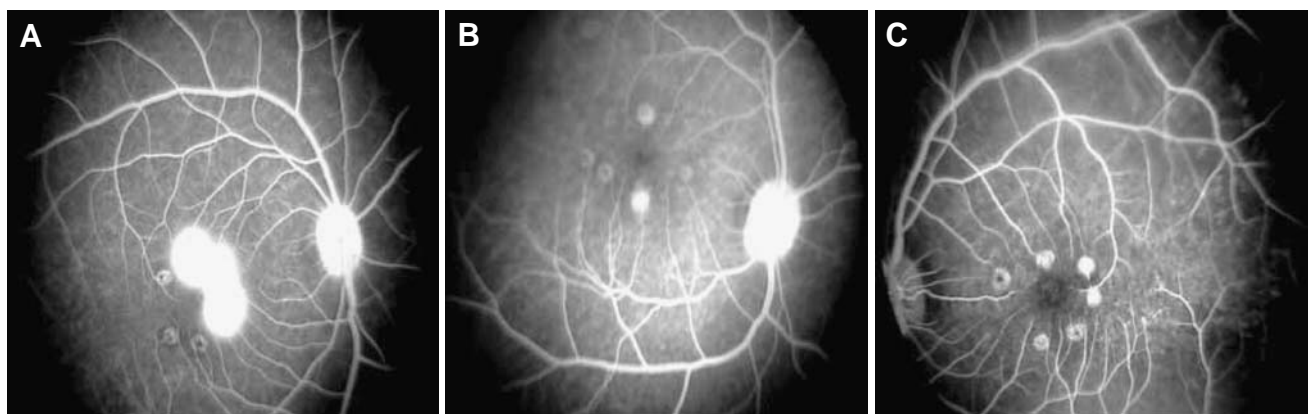
**Optical Coherence Tomography Examination.** Under sedation, the animals were fixed to keep eyes open and maintain the position of the head. OCT scan was applied using Stratus OCT™ model 3000 (Carl Zeiss Meditec, Dublin, CA, USA). Fast macular scan procedure was applied to each eye of monkey day 20 after laser injury.

**Color Photography and Fluorescein Fundus Angiography.** The animals were sedated with intravenous 2.5% soluble pentobarbitone (1 mL/kg). Eyelids were fixed to keep the eye open. Each animal was placed on an ophthalmology restraint stand to maintain the position of the head during photography. Photographs were taken using a fundus camera (FF450<sup>plus</sup> IRu Retina Camera, Software Visupac version 3.5, Carl Zeiss Meditec AG, Jena, Germany). Before administration of fluorescein dye, color photographs in the full view were firstly taken. Then, fluorescein dye (20% fluorescein sodium; 0.05 mL/kg) was injected via a vein of lower extremity. Photographs were taken at several time points after dye injection, including the arterial phase, early arteriovenous phase, and several late arteriovenous phases to

**Table III.** KH902 Serum Pharmacokinetics After Intravitreal Injection ( $n=2$ )

	No. 1	No. 2
Compartmental parameters		
$k_a$ (L/h)	0.0829	0.0494
$k_e$ (L/h)	0.0068	0.0056
CL(L/h/kg)	0.0006	0.0004
$T_{1/2\alpha}$ (h)	101.91	124.34
lagtime(h)	3.1427	3.1334
Noncompartmental parameters		
$T_{max}$ (h)	26.00	42.00
$C_{max}$ (ng/mL)	5.012	5.705
$AUC_{(0-168)}$ (ng/mL*h)	843.831	1209.059
$AUC_{(0-\infty)}$ (ng/mL*h)	898.886	1336.725
$MRT_{(0-168)}$ (h)	127.909	145.799
$MRT_{(0-\infty)}$ (h)	148.895	178.610

$k_a$  Absorption rate constant,  $k_e$  elimination rate constant, CL clearance,  $T_{1/2}$  half life time,  $T_{max}$  time of maximum concentration,  $C_{max}$  maximum concentration,  $AUC_{(0-168)}$  area under the curve until the last measurable concentration (168 h), and  $AUC_{(0-\infty)}$ , area under the curve from 0 to infinity,  $MRT$  mean residence time



**Fig. 3.** Late arteriovenous phase of fluorescein angiography demonstrating choroidal neovascularization 20th day after laser burn. **A** The angiography of control group which received intravitreal injection of phosphate buffer only. **B** The angiography of KH902 treatment group once a week for four doses. **C** The angiography of KH902 treatment group biweekly for two doses.

monitor leakage of fluorescein associated with CNV lesions. Color fundus photography and fluorescein angiography were used to detect and measure the evidence and extent of leakage of CNV in a masked fashion. Angiographically, the laser spot is hypofluorescent at early phase. If CNV is present, hyperfluorescence develops around the laser spot, which progresses to late diffuse leakage with dye pooling in the serous detachment surrounding the burn area. The leakage was graded on a standardized scale of 1 to 4. Grading scores were defined as the followings: (1) no hyperfluorescence; (2) hyperfluorescence without leakage; (3) early hyperfluorescence and late mild leakage; (4) early hyperfluorescence and late severely dye leakage which transits beyond the borders of the burn area. Grade 4 was defined as clinically significant fluorescence leakage of classic experimental CNV (7).

#### Statistical Analysis

Data are presented as mean $\pm$ SD and analyzed by SPSS 13.0 software. Difference among mean of the groups is determined with ANOVA. Comparison is considered to be statistically significant if  $p < 0.05$ . When a significant difference is determined, the Dunnett post hoc analysis is used.

## RESULTS

#### Biological Activity of KH902 *In Vitro*

KH902 has a relatively low PI of 6.13~6.81, according to the result of IEF analysis and KH902 presents high binding

affinity to VEGF with  $IC_{50}$  between 7~15 pM. Lucentis mean  $IC_{50}$  is 343 pM. (Fig. 1) The binding of KH902 to VEGF can block VEGF-induced HUVEC proliferation with  $EC_{50}$  28 pM as shown in Fig. 2. While  $EC_{50}$  is about 50 pM for Lucentis, the half magnitude of KH902 bioactivity.

#### KH902 Distribution in Eyes and Serum Pharmacokinetics

After a single intravitreal injection of KH902 into rhesus monkeys, ELISA assay showed that it was detected in several ocular tissues and serum for over 15 days. Although KH902 level was the highest in vitreous humor, the surrounding tissue including retina and choroid also could be detected 15 days after dose (Table II). KH902 began to be detected in serum 4 h after ITV administration and reached maximum concentration ( $C_{max}$ ) of about 5 ng/mL 34 h after dose ( $T_{max}$ ), which was over 1,000 folds lower than vitreous concentration. And KH902 was hardly detected in serum 15 days after dose. The  $t_{1/2}$  was approximately 4~5 days (Table III).

#### Safety and Efficacy of KH902 on Pathological Neovascularization

A few eyes among all monkeys developed a mild conjunctiva hemorrhage 1 day after injection which resolved to great degree 3 days later. And all eyes did not show evidence of inflammation according to the result of ophthalmological examination. No other abnormalities were observed.

The fluorescein angiographic findings in the animals demonstrated that the hyperfluorescence spots with fluores-

**Table IV.** The Hyperfluorescence Spots 20th Day After Laser

Groups	Eyes	Laser spots	Grade 4 hyperfluorescence spots number (%)	Hyperfluorescence spots per eye
Control	4	25	12 (48)	3 $\pm$ 1.6
KH902 treatment weekly	4	24	2 (8) <sup>a</sup>	0.5 $\pm$ 0.5*
KH902 treatment biweekly	4	24	1 (4) <sup>a</sup>	0.25 $\pm$ 0.4*

<sup>a</sup> Compared with control group, difference of grade 4 hyperfluorescence spots number is significant,  $p < 0.05$

cence leakage were less in both KH902 treatment groups than that in control group 20 days after dosage. Examples of angiographic appearance were demonstrated in Fig. 3. And what's more, there was no significant difference in hyperfluorescence spots number between the two regimens of KH902 (Table IV).

OCT scan was further performed to lineate the area of CNV leakage, which was observed in fluorescein angiograph. In the eyes of control group, the high reflect light echogenic mass similar to human CNV was detected by OCT scan day 20 after laser burn. In the two KH902 treatment groups, those laser spots with no leakage in FFA were also detected no echogenic mass and the images of the macula central fovea could be clearly discerned (Fig. 4).

To investigate the efficacy of KH902 on pre-existed CNV, 40 days after laser when the CNV was evidenced by ocular examination, control monkey eyes were re-divided into two groups with the left eye administered single 640  $\mu$ g KH902 and the right eye administered phosphate buffer. The fluorescein angiographic results showed that the study eye almost recovered 7 days after KH902 treatment while the leakage of hyperfluorescence spots still existed in the fellow eye without marked evidence of recovery (Fig. 5).

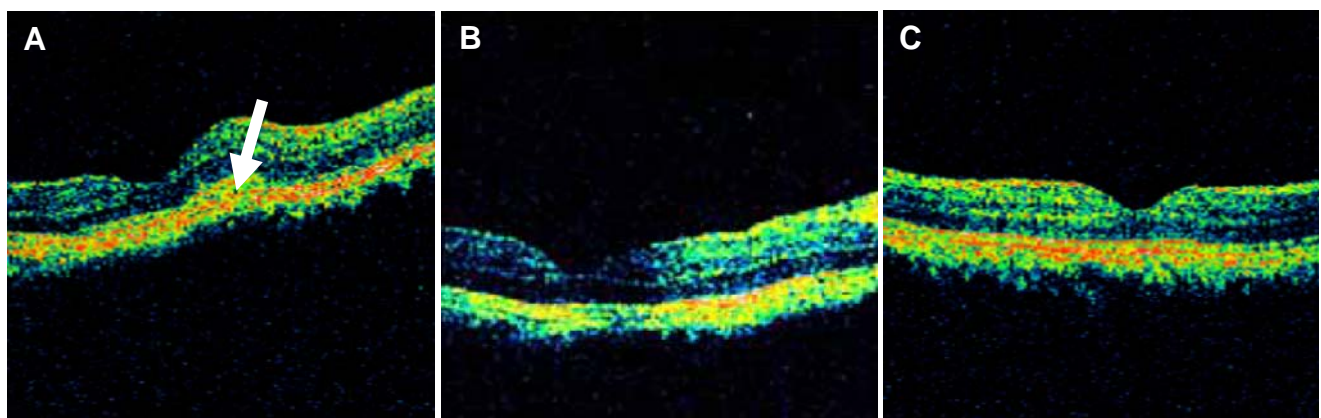
## DISCUSSION

VEGF is believed to be a central mediator of pathological angiogenesis in response to hypoxia or other stimulus. It can increase permeability of blood vessels and enhance neovascularization by association with VEGF receptors (8,9). Therefore, Many approaches for antagonizing VEGF are being considered. Up to now, Two anti-angiogenic therapies are approved for the treatment of wet AMD in the USA: Macugen (pegaptanib), a VEGF aptamer marketed by OSI and Pfizer, and Lucentis, an Avastin-related anti-VEGF antibody fragment marketed by Genentech. Another VEGF blocker under development, VEGF-Trap, is a fusion protein of domain 2 from VEGF receptor 1 and domain 3 from VEGF receptor 2 with human IgG Fc. It has a high affinity with VEGF and blocks all VEGF-A isoforms and placental growth factors. According to preclinical and clinical trial, they all demonstrate

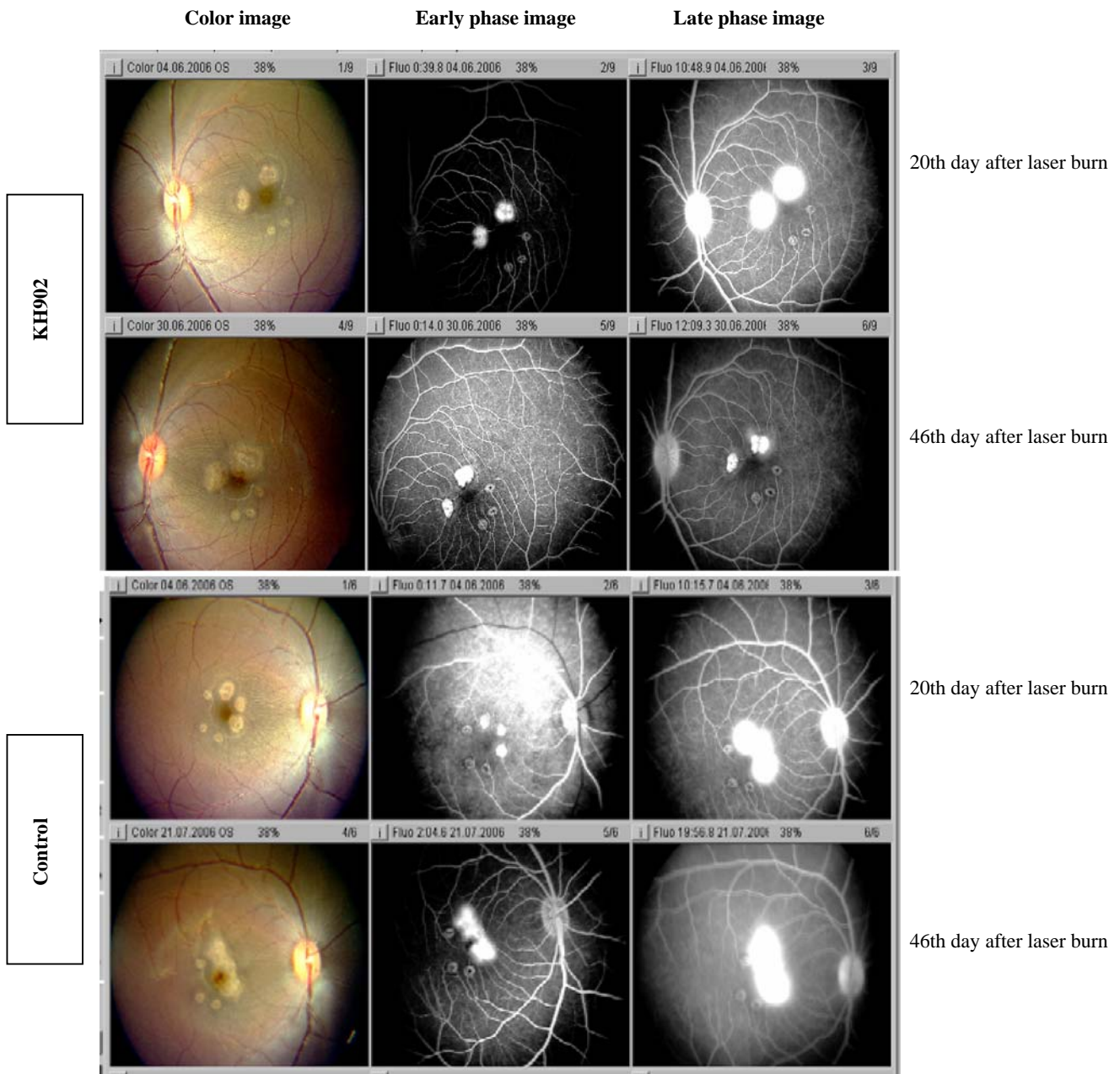
encouraging results by intravitreal delivery to AMD patients. However, these approaches have some concerns, because repeated intraocular injections carry risks of retinal detachment and endophthalmitis. Therefore, the optimization of VEGF antagonist is still preferable.

KH902, a recombinant fusion protein similar to VEGF-Trap, is designed to efficiently bind free VEGF and then block the VEGF-induced neovascularization implicated in CNV development. It combines ligand binding elements taken from the extracellular domain 2 of VEGF receptors 1 (Flt-1) and extracellular domain 3 of VEGF receptors 2 (KDR) fused to the Fc portion of human IgG1. The molecule uniquely contains an extracellular domain 4 of VEGF receptors 2 (KDRd4) which can improve the three-dimensional structure and increase the dimerization efficiently (10, 11) so that KH902 presents high affinity with VEGF. From VEGF binding assay, mean  $IC_{50}$  was 10 pM and the affinity of KH902 was over 30 times that of Lucentis, approved by FDA for wet-AMD in fashion. Binding of KH902 to VEGF can prevent the interaction of VEGF to its receptors on the surface of endothelial cells with  $EC_{50}$  28 pM, equally more efficient than Lucentis. Meanwhile, KDRd4 degrades the isoelectric point (PI) of KH902, which maintains the soluble state of the active proteins and may thus prolong the clearance time of KH902 in the vitreous. KH902 PI is 6.13~6.81, lower than PI 8.82 of VEGF Trap (12).

The availability of KH902 to the retina and choroid is important to treatment of the angiogenesis-related diseases like AMD. Previous studies indicate that drug clearance from the vitreous depends on molecular size (13). To investigate the ability of intravitreally administrated KH902 with molecular size 143 kD to reach the desired site of action, ocular and systemic levels were analyzed by ELISA. The results demonstrated that KH902 in the vitreous humor can be cleared from that region and be well distributed into the surrounding tissues, retina and choroid for a relatively long period. Retinal exposure to KH902 at 15 days was still 1,000-fold larger than retinal exposure to VEGF (14), suggesting that KH902 level provides most inhibition of VEGF based on *in vitro* studies. The approximate concentration was measured in chorioid in the 7 days (1.99  $\mu$ g/g) and 15 days (1.43  $\mu$ g/g)



**Fig. 4.** OCT images demonstrating choroidal neovascularization 20th day after laser burn. **A** Control group eye, there was a high reflect light echogenic mass beneath retina and adjoin retina (*white arrow head*) became thick due to local tissue edema. The integrity of retina pigmental epithelial was broken down; **B** KH902 treatment eye at 1-week interval; **C** KH902 treatment eye at 2-week interval, there was distinct retina and choroidal structure. No high reflect light echogenic mass was observed and the layer of retina pigmental epithelial was integrity. The shape of macular central fovea was discerned.



**Fig. 5.** Color photography and fluorescein angiography of left eye which received KH902 640  $\mu\text{g}/40 \mu\text{L}$  and right control eye which received phosphate buffer 40 days after laser burn in the pilot treatment on pre-existed CNV. Baseline angiogram shows leakage from the choroidal neovascularization in bilateral eyes, taken at 20th day after laser burn. At day 46 after laser burn, also seventh day after KH902 treatment, there is regression of leakage from the choroidal neovascularization (row 2). In the right control eye, there is no evidence of alleviating leakage (row 4).

after dose may also contribute to the similar effect at 1- or 2-week dosing intervals.

The well established model of laser-induced CNV in monkeys was taken in this study to evaluate KH902 efficacy *in vivo*. Its result showed that KH902 could attenuate the appearance of leaking CNV lesions when KH902 was co-administrated with laser treatment. This indicates that KH902 prevents the neovascularization process induced by laser and KH902 injection at either 1- or 2-week intervals is beneficial to CNV prevention without significant difference. In one side, longer interval is beneficial to reduce the risk of intravitreal injection. In the other side, the study suggests that KH902 is

well tolerated even by weekly repeated dose. In addition to KH902 prevention on the growth of CNV, the phase II assay was added to investigate KH902 effect on pre-existed leaky CNV. When single dose of KH902 was given to control eye with active CNV leakage 40 days after laser, KH902 still reduced the leakage of CNV, defined angiographically. The regression of hyperfluorescence spots hints KH902 blockage on pre-existed leaky CNV. This effect was further illustrated in another study (6).

In our study, no marked adverse effect including ocular inflammation was seen, which indicates good tolerance to KH902 at repeated dose of 640  $\mu\text{g}$ . It has entered phase I

trial in 2008 and four AMD patients receiving a single ITV dose of 0.05 mg per eye have elevation of average 20 letters in BCVA during 42-day observation period. Therefore, KH902 may be a new promising agent in treating human CNV-related AMD.

## ACKNOWLEDGEMENTS

The authors would like to thank Bin Liu and his colleagues of the National Chengdu Center for Safety Evaluation of Drugs for they provide and administrate the experimental monkeys.

## REFERENCES

1. D. S. Friedman, B. J. O'Colmain, B. Muñoz, *et al.* Prevalence of age-related macular degeneration in the United States. *Arch. Ophthalmol.* **122**:564–572 (2004). doi:10.1001/archophth.122.7.1019.
2. Age-Related Eye Disease Study Research Group. Potential public health impact of age-related Eye Disease Study results: AREDS report. *Arch. Ophthalmol.* **121**(11):1621–1624 (2003). doi:10.1001/archophth.121.11.1621.
3. H. M. Leibowitz, C. E. Krueger, L. R. Maunders, *et al.* The Framingham Eye Study monograph: an ophthalmological and epidemiological study of cataract, glaucoma, diabetic retinopathy, macular degeneration, and visual acuity in the general population of 2631 adults, 1973–1975. *Surv. Ophthalmol.* **24** (suppl.):335–610 (1980). doi:10.1016/0039-6257(80)90015-6.
4. A. Otani, H. Takagi, H. Oh, S. Koyama, Y. Ogura, M. Matumura, and Y. Honda. Vascular endothelial growth factor family and receptor expression in human choroidal neovascular membranes. *Microvasc. Res.* **64**:162–169 (2002). doi:10.1006/mvres.2002.2407.
5. J. Bainbridge, A. Mistry, M. D. Alwis, E. Paleolog, A. Baker, A. J. Thrasher, and R. R. Ali. Inhibition of retinal neovascularization by gene transfer of soluble VEGF receptor sFlt-1. *Gene Ther.* **9**:320–326 (2002). doi:10.1038/sj.gt.3301680.
6. M. Zhang, J. Zhang, M. Yan, *et al.* Recombinant anti-vascular endothelial growth factor fusion protein efficiently suppresses choroidal neovascularization in monkeys. *Molec. Vis.* **14**:37–49 (2008).
7. M. G. Krzystolik, M. A. Afshari, A. P. Adamis, J. Gaudreault, E. S. Gragoudas, N. A. Michaud, W. J. Li, E. Connolly, C. A. O'Neill, and J. W. Miller. Prevention of experimental choroidal neovascularization with intravitreal anti-vascular endothelial growth factor antibody fragment. *Arch. Ophthalmol.* **120**:338–346 (2002).
8. D. R. Senger, S. j. Galli, A. M. Dvorak, *et al.* Tumor cells secrete a vascular permeability factor that promotes accumulation of ascites fluid. *Science.* **219**:983–985 (1983). doi:10.1126/science.6823562.
9. D. W. Leung, G. Cachianes, W. J. Kuang, *et al.* Vascular endothelial growth factor is a secreted angiogenic mitogene. *Science.* **246**:1306–1309 (1989). doi:10.1126/science.2479986.
10. K. Suto, Y. Yamazaki, T. Morita, and H. Mizuno. Crystal structures of novel vascular endothelial growth factors (VEGF) from snake venoms: insight into selective VEGF binding to kinase insert domain-containing receptor but not to fms-like tyrosine kinase-1. *J. Biol. Chem.* **80**:2126–2131 (2005).
11. J. C. Luo, S. Yamaguchi, A. Shinkai, K. Shitara, and M. Shibuya. Significant expression of vascular endothelial growth factor/vascular permeability factor in mouse ascites tumors. *Cancer Res.* **58**:2652–2660 (1998).
12. J. Holash, S. Davis, N. Papadopoulos, *et al.* VEGF-Trap: A VEGF blocker with potent antitumor effects. *Proc. Natl. Acad. Sci. U.S.A.* **99**(17):11393–11398 (2002). doi:10.1073/pnas.172398299.
13. D. M. Maurice, and S. Mishima. Ocular pharmacokinetics. In M. Sears (ed.), *Pharmacology of the Eye*, Springer, Berlin, 1984, pp. 19–116.
14. J. Gaudreault, D. Fei, J. Rusit, *et al.* Preclinical pharmacokinetics of ranibizumab(rhufabv2) after a single intravitreal administration. *Invest. Ophthalmol. Visual Sci.* **46**(2):726–733 (2005). doi:10.1167/iops.04-0601.